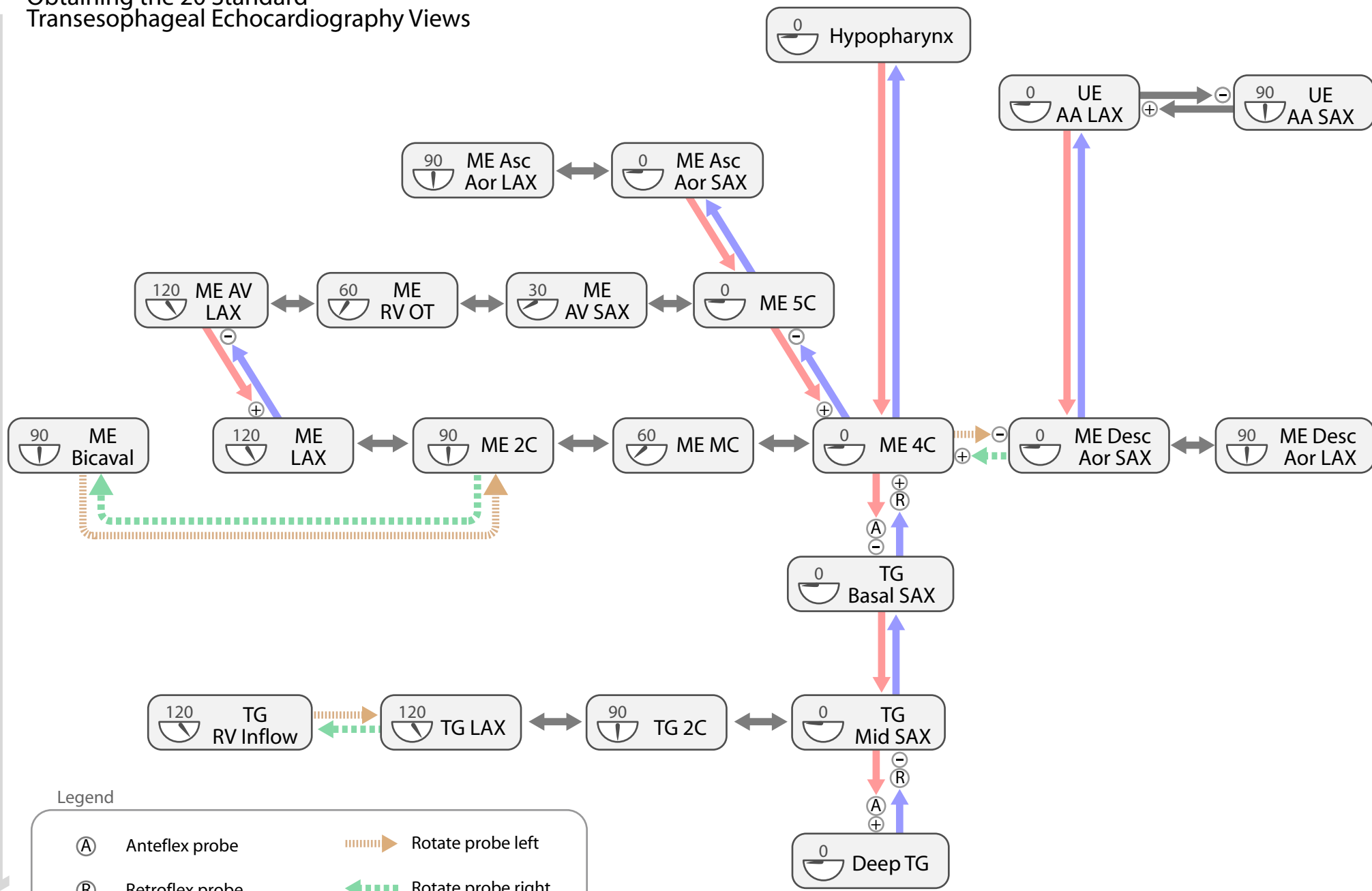


Obtaining the 20 Standard Transesophageal Echocardiography Views

Probe Depth



Legend

- (A) Anteflex probe
- (R) Retroflex probe
- ⊖ Decrease omniplane depth (display depth)
- ⊕ Increase omniplane depth (display depth)
- ↔ Change omniplane angle
- Rotated arrow Rotate probe left
- Rotated arrow Rotate probe right
- Red arrow Increase probe depth
- Blue arrow Decrease probe depth
- 90° icon Omniplane angle

2C - Two Chamber
 4C - Four Chamber
 5C - Five Chamber
 AA - Aortic Arch
 AV - Aortic Valve

Asc Aor - Ascending Aortic
 Desc Aor - Descending Aortic
 OT - Outflow Tract (Inflow-Outflow)
 LAX - Long Axis
 MC - Mitral Commissural

ME - Mid Esophageal
 RV - Right Ventricle
 SAX - Short Axis
 TG - Transgastric
 UE - Upper Esophageal